


PATIENT

Gideon Vaughan

SPECIES

Feline

BREED

DSH

SEX

Female Spayed

AGE

13 years

WEIGHT

9.5lbs

INTERPRETED BY

 Maggie Machen Lamy,
 DVM, DACVIM
 (Cardiology)

IMAGING PERFORMED BY

Kelly Vazquez, CVT

HOSPITAL NAME

 Animal General on
 Hudson

REFERRING VET

Dr. Ng

INVOICE

21160

DATE

9/22/21

PRESENTING CLINICAL SIGNS

History: Recheck echo. History of heart murmur. No current medications.

-Pertinent previous echo findings (12/2020 MML): Normal unknown murmur; small hypoechoic lesion along the right heart.

ECHOCARDIOGRAM FINDINGS

2D, m-mode, color flow and doppler imaging is available. The left ventricular wall is normal in dimension. There is a diffusely hyperechoic endocardium consistent with age-related fibrosis. Minimal remodeling. The papillary muscles are hyperechoic. The left atrium is normal in size. The right atrium is normal in size. The right ventricle appears normal. The mitral valve is normal in structure and mobility. No MR. The tricuspid valve appears normal in structure and mobility. Trace TR. Blood flow through both the LVOT and RVOT are normal in velocity. No effusions. Hypoechoic lesion not appreciated on this exam.

CARDIAC CHART

FELINE CARDIAC PARAMETERS	BODY WEIGHT (kg)	HR (BPM)	IVSd (cm) (Moise, Pipers)	LVIDd (cm) (Moise, Pipers)	LVWd (cm) (Moise, Pipers)	FS (%)	EF (%)
NORMAL PARAMETER	-----	150-240	0.35-0.55	<2 (mean 1.5)	3.5-0.55	35-67	80-100
PATIENT	4.3	130	0.45	1.3	0.46	47	82
FELINE CARDIAC PARAMETERS	LA/AO (Boon)	LA/AO HEART BASE (Swe) (Abbott)	LA 2D short axis Base view (cm) (Abbott)		LVOT VEL (m/s)	RVOT VEL (m/s)	E max (m/s)
NORMAL	<1.5	<1.3	<1.2		<1.6	<1.3	<0.9
PATIENT	1.1	1.3	1.2		0.93	0.8	NM

**Note: All measurements based upon multi-modal images and methods. An average value is reported.*
 Adapted from June Boon, Veterinary Echocardiography, 1998
 Abbott J & MacLean H JVIM 2006;20: 111-119, Moise et al. Am J Vet Res 47:1476, 1986. Pipers et al. Am J Vet Res 40:882, 1979.

INTERPRETATION OF THE FINDINGS & FURTHER RECOMMENDATIONS

Unchanged geriatric cardiac structure and function with mild remodeling and fibrosis. Compared to the prior study there is no evidence of progression with no LVH and no left atrial enlargement. The previously noted hypoechoic lesion along the right heart is not apparent on this exam. While this is easily missed in the absence of effusion and may still be present, we can at least say there is no obvious progression in size which is good news.

Given these findings, no medications are indicated.

No cardiac contraindication for general anesthesia. Should fluid or steroid therapy be indicated in the future, any cat should be monitored for intolerance (changes in RR/RE).

Monitor at home for signs of cardiac compromise, including respiratory changes and/or signs of a blood clot event (paralysis, neurologic changes).



PATIENT

Gideon Vaughan

Recommend recheck echocardiogram annually to screen for development of disease the pre-existing murmur may mask.

SPECIES

Feline

BREED

DSH

SEX

Female Spayed

AGE

13 years

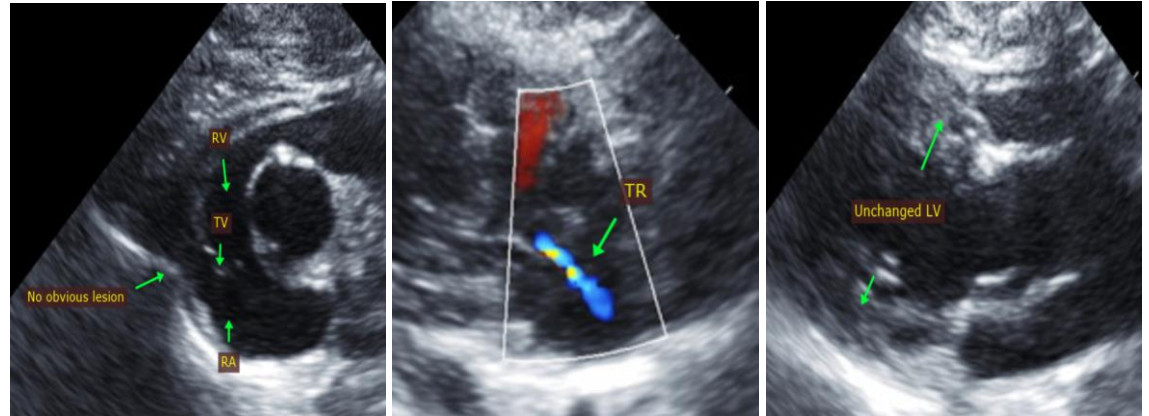
WEIGHT

9.5lbs

INTERPRETED BY

Maggie Machen Lamy,
DVM, DACVIM
(Cardiology)

IMAGES



The information and recommendations provided are based on the images presented by the referring veterinarian. No evaluation can be communicated regarding pathology that was not visible in the image/video clips provided.

Thank you for this referral. This report was generated using transcription software, and minor dictation errors may be present. If the clinical or image interpretation does not parallel your findings or if I can be of any further assistance, please contact me.

Maggie Machen Lamy, DVM
Diplomate of the American College of Veterinary Internal Medicine (Cardiology)
info@sonopath.com

IMAGING PERFORMED BY

Kelly Vazquez, CVT

HOSPITAL NAME

Animal General on Hudson

REFERRING VET

Dr. Ng

INVOICE

21160

DATE

9/22/21